



## A Case of Mature Orbital Teratoma in a Simmental Breed Calf

Ayfer Yıldız Uysal<sup>1,a,\*</sup>, Burhan Özba<sup>2,b</sup>, Serpil Dağ<sup>1,c</sup>, Ersin Tanrıverdi<sup>2,d</sup>, Enver Beytut<sup>1,e</sup>, Hilmi Nuhoglu<sup>1,f</sup>, Mizgin Kengiş<sup>1,g</sup>, Ahmet Melih Acar<sup>1,h</sup>

<sup>1</sup>Department of Veterinary Pathology, Faculty of Veterinary Medicine, Kafkas University, Kars, Türkiye

<sup>2</sup> Department of Veterinary Surgery, Faculty of Veterinary Medicine, Kafkas University, Kars, Türkiye

\*Corresponding author

### Case Report

History

Received: 19/11/2024

Accepted: 05/05/2025

### ABSTRACT

Teratoma is defined as a congenital neoplasm containing elements from all three germinal cell layers (ectoderm, mesoderm, endoderm) and classified as mature, immature, and malignant according to their cell structure. Mature dermoid cysts, which are among teratomas, are benign tumors that represent the simplest form of teratoma. However, to date, detailed research was not found on the ocular dermoid cysts in calves. No similar case was found in the literature review, and we believe that this study will make significant contributions to the literature.

**Keywords:** Calf, Dermoid cyst, Mature, Orbital, Teratoma, Tumor

## Simmental Irkı Bir Buzağıda Olgun Orbital Teratom Olgusu

Süreç

Geliş: 19/11/2024

Kabul: 05/05/2025

Copyright



This work is licensed under  
Creative Commons Attribution 4.0  
International License

### Öz

Teratom, her üç germinal hücre katmanından (ektoderm, mezoderm, endoderm) elemanlar içeren ve hücre yapılarına göre matür, immatür ve malign olarak sınıflandırılan konjenital bir neoplazm olarak tanımlanır. Teratomlar arasında yer alan matür dermoid kistler, teratomun en basit formunu temsil eden iyi huylu tümörlerdir. Ancak bugüne kadar buzağılarda oküler dermoid kistlerle ilgili detaylı bir araştırmaya rastlanmamıştır. Literatür taramalarında benzer bir vakaya rastlanılmamış olup, yapmış olduğumuz bu çalışmanın literatüre önemli katkıları olacağı kanaatindeyiz.

**Anahtar Kelimeler:** Buzağı, Dermoid kist, Olgun, Orbital, Teratom, Tümör

<sup>a</sup> mail: yildizayfer360@gmail.com

<sup>c</sup> mail: serpildag06@hotmail.com

<sup>e</sup> mail: enverbeytut@hotmail.com

<sup>g</sup> mail: mizginkengis@gmail.com

<sup>b</sup> ORCID: 0000-0002-6569-5435

<sup>d</sup> ORCID: 0000-0001-7667-689X

<sup>f</sup> ORCID: 0000-0003-3360-2940

<sup>h</sup> ORCID: 0009-0000-2470-3753

<sup>b</sup> mail: bozba@hotmail.com

<sup>d</sup> mail: ersintanriverdi@hotmail.com

<sup>f</sup> mail: hilminuhoglu@gmail.com

<sup>h</sup> mail: a.melik\_acar@hotmail.com

<sup>e</sup> ORCID: 0000-0002-0081-7059

<sup>g</sup> ORCID: 0000-0001-8502-2070

<sup>h</sup> ORCID: 0000-0003-2530-2542

<sup>h</sup> ORCID: 009-0006-6852-649X

**How to Cite:** Yıldız Uysal A, Özba B, Dağ S, Tanrıverdi E, Beytut E, Nuhoglu H, Kengiş M, Acar AM (2025) A Case of Mature Orbital Teratoma in a Simmental Breed Calf, Turkish Veterinary Journal, 7(1): 31-35

### Introduction

Congenital teratomas are rare, usually benign neoplasms originating from cells that make up the three germinal cell layers (Chaudhry et al., 2021). Teratomas are classified according to their cellular structure as mature, immature, and malignant, with mature teratomas being the most common. Dermoid cysts, which are included in mature teratomas, are benign tumors and represent the simplest form of teratoma (Ahmed and Lotfollahzadeh, 2022). Dermoid cysts can often be found on the eyelids, conjunctiva, nictitating membrane, cornea, or the entire eye (Brudenall et al., 2008). These tumoral formations, which can be unilateral or bilateral, may form only in the lateral angle of the eye and in a very narrow area that does not affect vision much, or they may form in a widespread manner that covers the entire eye (Kajal et al., 2024). Orbital dermoids cause chronic epiphora, keratitis, lacrimation and

keratoconjunctivitis by constantly irritating the eye and surrounding tissues (Adıyeke et., 2014). Dermoid cysts usually contain hair, keratin, and sebum, and these formations cause progressive enlargement of the tumor structure, making the cyst more clinically obvious (Barkyoumb and Leipold, 1984). Depending on the extent and location of orbital dermoid cysts and available equipment, excision of the tumoral structure is performed either surgically or by cryotherapy, hyperthermia, radiofrequency, or a combination of these methods (Sarrafzadeh-Rezaei et al., 2007). Dermoids have been reported in dogs and cattle, calves, cats, and rarely in other domestic animals such as horses, donkeys, buffaloes, goats, sheep, camels, and pigs, wild animals such as white-tailed deer, red deer, lions, and antelopes, and birds. However, there is no detailed research and long-term study on the incidence of ocular dermoid cysts in

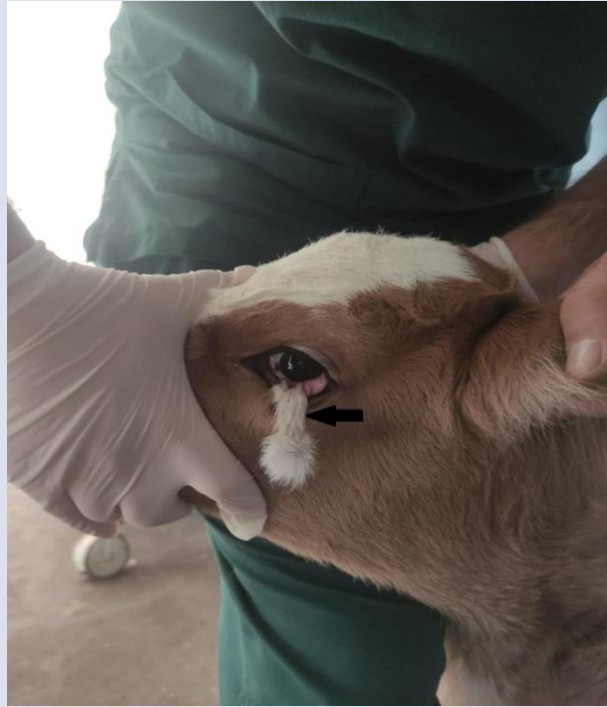calves (Sarangom et al., 2016). The aim of this case report was to describe the clinical and pathological findings of mature orbital teratoma in a newborn calf.

## Materyal ve Yöntem

### Case Report

This case is a 6-day-old male Simmental calf that was brought to the Veterinary Clinic of the Kafkas University Faculty of Veterinary Medicine with a complaint of a soft mass in the left eye. During the dpatient's owner, it was determined that the mass, localized on the left eye conjunctiva and lower eyelid, was a 5 cm long, hairy and skin-like tissue extending out of the eye (Figure 1). A detailed eye examination revealed that the mass was not associated with the cornea and that the eye had the ability to see. After obtaining consent from the animal owner, preparations were made for total surgical removal of the mass. The area was shaved and cleaned for surgery, which was performed under sedation and local infiltration anesthesia. The calf was sedated with xylazine HCl (0.2 mg/kg, IM, Rompun®, Bayer) and placed in the lateral decubitus position on the operating table. Local infiltration anesthesia was achieved by injection of lidocaine HCl (10 ml. Vilcain®, Vilsan) at the base of the third eyelid and subconjunctivally for regional anesthesia. Asepsis and

antisepsis of the region were provided and the eye and its surroundings were limited with a sterile drape. A circular incision was made with a scalpel in the area where the mass was connected to the lower eyelid and conjunctiva, and the boundaries of the mass to be excised were determined. The mass was released with blunt dissection, and the blood vessels responsible for the nutrition of the mass were ligated with 4.0 absorbable suture material and the mass was completely removed. The region was closed with a simple continuous suture technique using the same suture material. The operation was terminated after the eye and its surroundings were washed with sterile 0.9% isotonic solution. In the postoperative period, tobramycin (3 mg/mL TOBRASED® 0.3% eye drops) eye drops were added to the treatment protocol three times a day to prevent infections that may be caused by pathogenic agents and to ensure rapid recovery. After the effects of sedation disappeared in the postoperative period, the patient was discharged after a clinical examination. Considering that the incision area was limited to the lower eyelid conjunctiva and was not directly connected to the external environment, no dressing was applied in the postoperative period. For prophylaxis purposes, it was recommended that the patient be kept separate from his peers and hospitalized in a clean environment.



*Figure 1. A Hairy mass extending down the conjunctiva and lower eyelid in the left eye (arrow).*

### Histopathological Method

Tissue samples were excised and sent to our department for histopathologic examination and fixed in 10% buffered formaldehyde solution for microscopic

examination. After routine tissue processing, paraffin blocks were prepared. Sections of 5 µm thickness were cut from the prepared paraffin blocks for hematoxylin and eosin (H&E) staining. The sections were examined under a light microscope (Olympus Bx53) and photographed.

### Histopathologic Results

Histopathologic examination of the tissue sample revealed that the tissue had the normal histological structure of skin and consisted of epidermis, dermis, and subcutis. The epidermal layer was observed to be lined with multilayered flat keratinized epithelial cells. Just below the epidermis, there was a dermis layer composed

of elastic fibers. In the dermis layer, blood vessels and well-developed hair follicles, sweat and sebaceous glands were observed. In addition, cartilage and muscle tissue formation were found in the subcutaneous layer of the tissue (Figure 2).

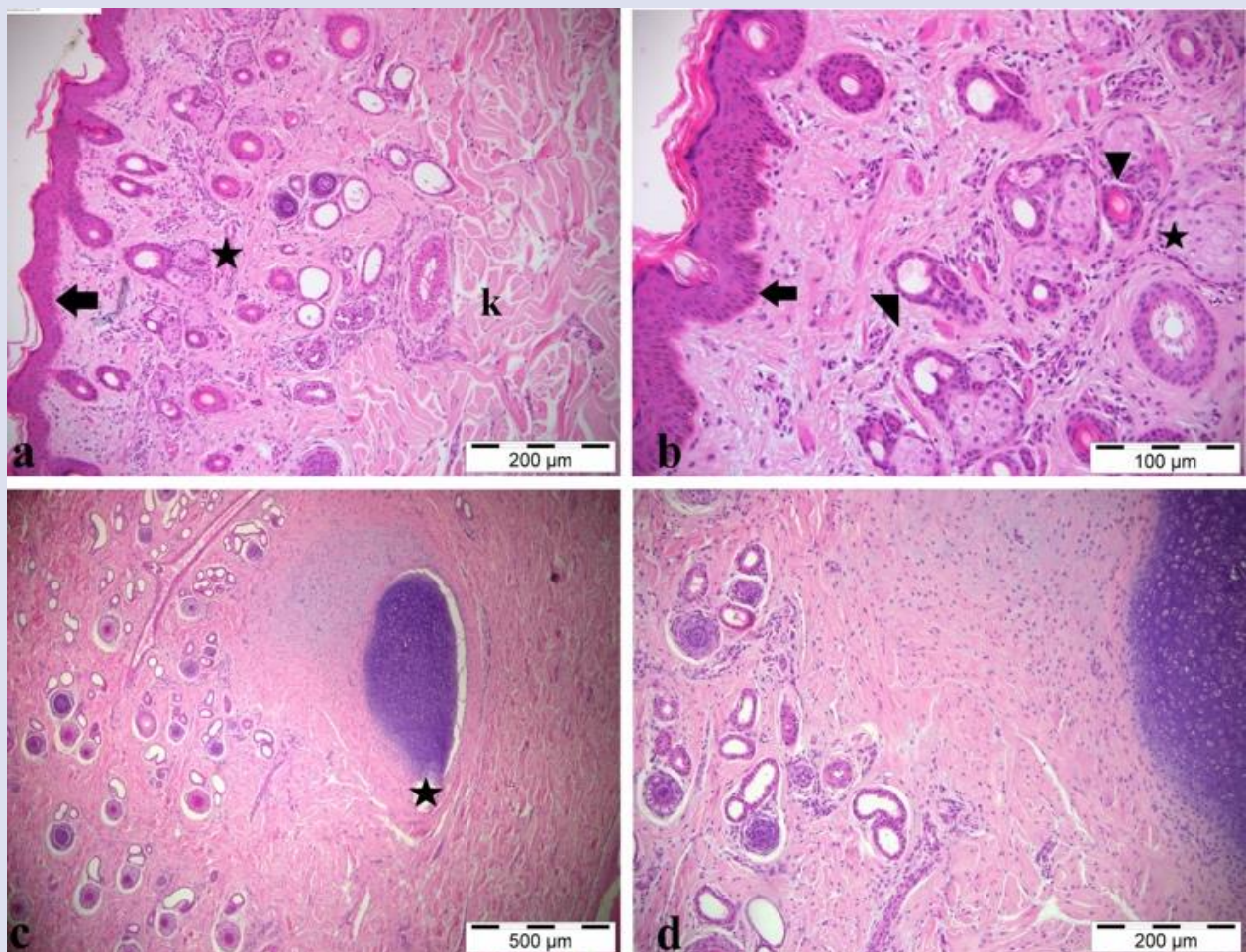


Figure 2. a) Orbital mature teratoma showing normal epidermal (arrow), dermal (asterisk), and muscular layers (k), hematoxylin and eosin (H&E), 200 µm. b) High magnification of epidermal (arrow) and dermal structures, including hair follicle (arrowhead), sweat glands (triangle), and sebaceous glands (asterisk), H&E, 200 µm. c) Cartilage structure formation in the subcutis (asterisk), H&E, 500 µm. d) Cartilage structure and skin attachment structures, H&E, 100 µm.

### Discussion

Teratomas account for approximately 6-10% of pediatric tumors in humans and are most commonly found in the testes, ovaries, or retroperitoneum. Congenital orbital teratomas are extremely rare and are among the tumors that require urgent attention (Tsoutsanis and Charonis, 2021). Dermoid cysts, also known as mature cystic teratomas, are rare congenital or acquired tumor-like developmental anomalies. The developmental mechanisms involved in the pathogenesis of ocular dermoids are not fully understood. The most likely mechanism is mesenchymal metaplasia (mainly of neural crest origin)

leading to abnormal differentiation of the surface ectoderm. The resulting dermoid is composed of ectodermal elements (keratinized epithelium, hair, sebaceous and apocrine glands) and mesenchymal elements (fibrous tissue, fat and cartilage) combined in varying proportions (Alam and Rahman, 2012, Oryan et al., 2012). There is a breed predisposition for ocular cystic dermoids, and they have been reported in Burmese cats, Dachshunds, Dalmatians, Doberman pinschers, Golden retrievers, German shepherds, Saint Bernards, and Quarterhorses. In cattle, ocular dermoids are not very common, with an estimated prevalence of 0.002%-0.4%. Ocular dermoids have been reported in almost all cattle breeds except Hereford, although with



low prevalence. These tumoral structures may be single or multiple, firm to fluctuant, well circumscribed, smooth and round, and usually the overlying skin is normal (Adiyeke et al., 2017, Brudenall et al., 2008). The material of this study was a 6-day-old Simmental calf. Ocular dermoids are very rare in calves and very few studies were found in the literature research. Ocular dermoids in domestic species can develop in a variety of locations, including the eyelids, conjunctiva (bulbar and palpebral), cornea, and nictitating membrane, and can occur unilaterally or in both eyes. In a study conducted in calves in 2019, Badanes and Ledbetter reported that cases of ocular dermoid cysts were more common in the left eye at the level of the caudus (Badanes and Ledbetter, 2019). Sarrafzadeh-Rezaei et al. reported in 2007 that in the left eye of a 2-day-old newborn female river buffalo (*Bubalus bubalis*) calf, a soft, fluctuant, fluid-filled, nontender, hyperemic ocular dermoid cyst was found in the inferior palpebral conjunctiva completely covering the orbit (Sarrafzadeh-Rezaei et al., 2007). In 2008, Brudenall et al. reported that dermoid cyst formation was observed in a 5-day-old Angus × Hereford female calf causing moderate blepharospasm, ulceration, and discharge in both eyes (Brudenall et al., 2008). In our case, the lesion was unilateral, localized to the left eye, and had a hard structure. Sarrafzadeh-Rezaei et al., 2007 reported that the microscopic mass consisted of epidermis, dermis, and skin appendages, some of the sebaceous glands had both intact and disintegrating sebum-containing secretory cells, and some parts had cystic structures (Sarrafzadeh-Rezaei et al., 2007). Brudenall et al. In 2008, in a case of dermoid cyst examined histopathologically, it was reported that the mass had normal skin histology and consisted of hair follicles, sebaceous and sweat glands, and a small number of inflammatory cells (Brudenall et al., 2008). Similar to Sarrafzadeh-Rezaei et al. (2007) and Brudenall et al. (2008), we observed from histopathologic examination that the mass we obtained had a normal skin structure and consisted of epidermis and dermis. The epidermis was lined with multilayered squamous keratinized epithelial cells, and the dermis contained well-developed, numerous hair follicles, sebaceous and sweat glands, and cartilaginous tissue formation. Considering that the mass contained both ectodermal and mesenchymal elements, its location and the time of its formation.

This study contributes to the literature on a very rare tumor type in ruminants by presenting a case of teratoma in a calf and constitutes an important reference in the veterinary field for the diagnosis, treatment and prognosis of similar cases. Intraoperative evaluation revealed that the mass had limited connection with the lower eyelid conjunctiva, was poor in terms of nerve tissue and blood vessels, and was not associated with the cornea, and the operative intervention was completed without any complications. Since the incision area had a contact

surface with the cornea, it is possible for a corneal lesion to form in the postoperative period. In order to prevent this situation, absorbable suture material was used and care was taken to ensure that the knot was buried between the wound lips. In addition, since the patient is a farm animal, recommendations were made to the patient's owner to provide optimal environmental conditions for the patient, taking into account the risk of postoperative contamination. In addition, it was recommended to keep her away from her peers during this period and to use antibiotic eye drops. Thus, possible infections were prevented and ideal wound healing was achieved within the desired period.

### Conflict of Interest

The authors declared that there is no conflict of interest.

### References

- Adiyeke, S.K., Kunak, D., & Canbeyli, İ. (2014). Periorbital Dermoid Kistlerin Retrospektif Değerlendirilmesi. *Turkish Journal of Ophthalmology*, 44(6), 461-464. doi:10.4274/tjo.04372.
- Ahmed, A., & Lotfollahzadeh, S. (2022). Cystic Teratoma. In *StatPearls*. StatPearls Publishing.
- Alam, M.M., & Rahman, M.M. (2012). A three years retrospective study on the nature and cause of ocular dermoids in cross-bred calves. *Open veterinary journal*, 2(1), 10–14.
- Badanes, Z., & Ledbetter, E.C. (2019). Ocular dermoids in dogs: A retrospective study. *Veterinary ophthalmology*, 22(6), 760–766. doi: 10.1111/vop.12647.
- Barkyoumb, S.D., & Leipold, H.W. (1984). Nature and cause of bilateral ocular dermoids in Hereford cattle. *Veterinary pathology*, 21(3), 316–324. doi: 10.1177/030098588402100309.
- Brudenall, D.K., Ward, D.A., Kerr, L.A., & Newman, S.J. (2008). Bilateral corneoconjunctival dermoids and nasal choristomas in a calf. *Veterinary ophthalmology*, 11(3), 202–206. doi: 10.1111/j.1463-5224.2008.00580.x.
- Chaudhry, R., Qamar, M.N., & Riaz, A. (2021). Mature Orbital Teratoma. *Journal of the College of Physicians and Surgeons-Pakistan:JCPS*, 30(5), 596–598. doi: 10.29271/jcpsp.2021.05.596.
- Kajal, G., Cui, D., & Winters, R. (2024). Malignant Orbital Tumors. *StatPearls*, 24(21):230-237.
- Oryan, A., Hashemnia, M., & Mohammadalipour, A. (2012). Dermoid cyst in camel: a case report and brief literature review. *Acta Veterinaria Scandinavica*, 21(5), 555–558. DOI: 10.1007/s00580-010-1128-9.
- Sarangom, S.B., Singh, K., Gopinathan, A., Sangeetha, P., Kallianpur, N., Shivaraju, S., Pravven, K., Sharma, D., & Singh, P. (2016). Ocular dermoids in crossbred Indian cattle: A comparative evaluation of four year (2012–2015) study results and literature reviews. *Adv Anim Vet Sci*, 4(1), 46-52. doi.org/10.14737/journal.aavs/2016/4.1.46.52.
- Sarrafzadeh-Rezaei, F., Farshid, A.A., & Saifzadeh, S. (2007). Congenital ocular dermoid cyst in a river buffalo (*Bubalus bubalis*) calf. *Journal of veterinary medicine. A, Physiology*,

pathology, clinical medicine, 54(1), 51–54. doi:  
10.1111/j.1439-0442.2007.00875.x.

Tsoutsanis, P.A., & Charonis, G.C. (2021). Congenital orbital  
teratoma: a case report with preservation of the globe and  
18 years of follow-up. BMC ophthalmology, 21(1), 456. doi:  
10.1186/s12886-021-02229-2.