



## Ultrasonographic Examination as a Useful Tool Diagnose a Plastic Foreign Body Causing Duodenal Obstruction in a Cat

Murat VURUCU\*<sup>1</sup>, Ozan AVCI<sup>2</sup>

<sup>1</sup>Erciyes Üniversitesi, Sağlık Bilimleri Enstitüsü Veteriner Fakültesi İç Hastalıkları Anabilim Dalı Kayseri, Türkiye

<sup>2</sup>Afyon Kocatepe Üniversitesi, Sağlık Bilimleri Enstitüsü Veteriner Fakültesi İç Hastalıkları Anabilim Dalı Afyon, Türkiye

Vurucu M 0000-0002-3791-7176

Avcı O 0000-0003-3941-6786

\*Corresponding Author's E-Mail: muratvurucu87@gmail.com

### Abstract

A 5-year-old, sterilized, mixed-breed female cat was referred to Veterinary Pet Clinic with a vomiting complaint. Treatment for gastrointestinal infection was initiated, but the cat was referred to the clinic again 24 hours later with severe vomiting, fasciculation, tremor, loss of pupillary reflex, and worsening general condition. In this case, ultrasonographic imaging was used instead of radiographic imaging, which is frequently employed as the first imaging method. The structure of a foreign body was observed during the ultrasonographic examination. When the foreign body was described, the patient's owner confirmed that her cat had a toy that was consistent with this description. Blood tests revealed hyponatremia, hypochloremia, and hypokalemia. Significant neurological findings (fasciculation and tremor) were observed. Hypochloremic metabolic alkalosis was diagnosed due to complete duodenal obstruction. After the patient's postoperative care was completed, full recovery was achieved.

Received 28 December 2019  
Accepted 1 September 2020  
Published 30 December 2020

### Key words:

Vomiting, tremor, foreign body, ultrasonographic examination

**Cite this article:** Vurucu M, Avcı O, (2020) Ultrasonographic Diagnosis of a Plastic Foreign Body Causing Duodenal Obstruction in a Cat. Turk Vet J, 2(2):74-79

### Bir Kedide Doudenal Obstruksiyona Neden Olan Plastik Yabancı Bir Cismin Faydalı Bir Tanı Metodu Olan Ultrasonografik Muayene İle Teşhisi

#### Özet

5 yaşında kısır dişi kedi (melez ırk), kusma şikayeti ile kliniğe getirildi. Gastrointestinal enfeksiyon tedavisi başlandı. 24 sonra kusma şikayetinin artarak devam ettiği ve genel durumun giderek kötüleştiği gözlemlendi. Fiziksel muayenede kas seğirmesi ve tremorlarıyla birlikte pupillar refleks kaybı tespit edildi. Bu vakada; sıklıkla ilk görüntüleme yöntemi olarak kullanılan radyografik görüntüleme yerine ultrasonografik görüntüleme kullanıldı. Ultrasonografik muayenede yabancı cismin tespiti yapıldı. Yabancı cisim tarif edildiğinde, hastanın sahibi, kedisinin bu tanıma uygun bir oyuncak olduğunu doğruladı. Kan tahlili sonuçlarında hiponatremi, hipokloremi ve hipokalemi mevcuttu. Belirgin nörolojik bulgular (kas seğirmeleri ve tremorları) gözlemlendi. Tam duodenal obstrüksiyonun neden olduğu hipokloremik metabolik alkalosis teşhisi konuldu. Hastanın postoperatif bakımları tamamlandıktan sonra tam bir iyileşme sağlandı.

**Anahtar Kelimeler:** Kusma, tremor, yabancı cisim, ultrasonografik muayene

### Introduction

Gastrointestinal foreign bodies are frequently seen in veterinary medicine, and they cause various clinical findings depending on the severity and duration of obstruction (Aranson ve ark., 2000). Mild clinical signs may be observed in partial obstructions in cats. Maldigestion and malabsorption symptoms may also be seen in these animals. Severe, dramatic clinical findings can be seen in complete obstruction (Papazoglou ve ark., 2003). Moreover, severe vomiting and diarrhea can be observed, possibly resulting in hypovolemia and septic shock in cats (Bebchuk, 2002).

Most obstructive, nonlinear foreign bodies cause edema of the intestinal wall and progressive necrosis in the intestine. This situation cause the blood supply of the intestinal segment in conjunction with luminal distention. As a result, an ileus can be formed and the number of pathological intraluminal bacteria may increase, leading to a breakdown of the mucosal barrier and endotoxemia (Ellisson, 1993a).

Possible reasons for muscle tremors and twitching in cats can be listed as toxicities, encephalomyelitis, hereditary reasons, degenerative cerebral diseases,

hypokalemia, hepatic encephalopathy, and cat hyperesthesia syndrome. In addition, hypochloremic metabolic alkalosis with neural symptoms caused by gastrointestinal obstruction has been reported in cats (Jukes ve ark., 2017).

Radiographic and ultrasonographic imaging methods are frequently used for the diagnosis of gastrointestinal foreign bodies. These more effective methods are still to be discussed between inside by clinicians. This study was evaluated as a case report due to the use of ultrasonographic examination alone in the diagnosis of gastrointestinal foreign bodies.

## Case

A 5-year-old, sterilized, mixed-breed female cat was referred to Veterinary Pet Clinic with a complaint of vomiting. The cat's general condition was good, but the owner reported that it had vomited several times in one day before. The cat's body temperature was 39°C. Dehydration was not present, and the hemogram parameters were normal (Table 1). More detailed laboratory analysis and radiographic imaging were recommended to the patient's owner. However, the owner did not agree due to cost considerations. The patient was thought to have a gastrointestinal infection. First, treatment was started to cease vomiting and protect the stomach with maropitant (Cerenia, Zoetis, USA) and ranitidine (Ulcuran, Yavuz Farma, Turkey). An antibiotic (Enrofloxacin, Baytril, Germany) was also used to protect the cat from possible infection. The patient was referred to the clinic due to increased symptoms of vomiting and dehydration, lethargy, hypovolemia, fasciculation, and tremor 24 hours later. Thoracic and cardiac auscultation findings were normal. The abdomen was taut and painful on palpation. The body temperature was normal, at 37.6°C. Lactate ringer solution was administered to the patient intravenously until the laboratory results were obtained, from which, a foreign body causing gastrointestinal obstruction was suspected. The patient's Out of surface of abdomen was shaved. There was no abnormality in the liver or kidneys in the ultrasonographic examination. Dense content compatible with crystals was seen in the urinary bladder (Figure 1a). The stomach was filled with a large amount of liquid content (Figure 1b). The thickness of the stomach wall was normal, and edema was detected. The liquid content was observed in the pylorus and duodenum. An oval structure (foreign body) with a diameter of 15 mm was detected at the end of the content transition in the duodenum. This foreign

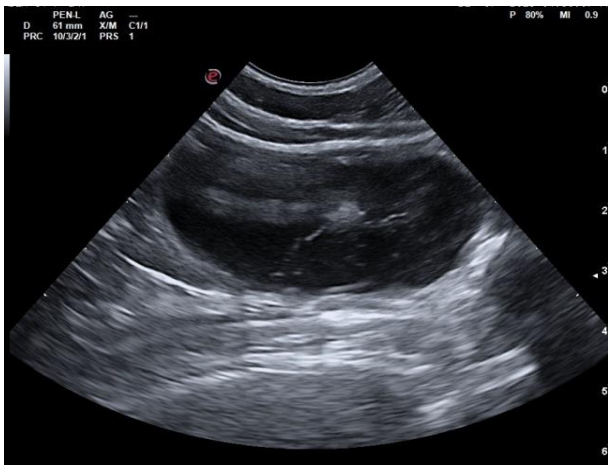
body had a hypoechoic external contour with acoustic shadowing, and the center of the foreign body was anechoic in ultrasonographic examination (Figure 2a). Multiple hyperechoic structures with small diameters resembling a serrated structure were detected in the scan sections toward the outer surface of the foreign body (Figure 2b). The object was described to the patient owner as detected in ultrasonographic examination. The patient owner said that there was a plastic ball with a serrated outer surface with which the cat frequently played.

The obtained laboratory results indicated decreased levels of the following parameters: sodium, at 141 mmol/L (normal range: 150–165 mmol/L); potassium, at 2.4 mmol/L (normal range: 3.5–5, mmol/L) and chlorine, at 104 mmol/L (normal range: 112–129 mmol/L). Meanwhile, the following parameters had increased levels: urea, at 27.77 mmol/L (normal range: 5.71–12.85 mmol/L); and glucose, at 18.21 mmol/L (normal range: 4.11–8.83 mmol/L). A 0.9% NaCl solution was given intravenously by changing the fluid treatment. The diagnosis of complete duodenal obstruction was made with the help of the present anamnesis, ultrasonographic imaging, laboratory results, and clinical findings. Before the operation, anesthesia was induced using xylazine HCl (Xylazinbio, Germany, 0.8 ml/kg IM) and ketamine HCl (Brema, Czech Republic 0.7 ml/kg IM and 0.1 ml/kg IM for maintenance in two different doses). The operation was started with a standard surgical procedure. The incision was started from the median line of the abdomen to the umbilical artery and reached the stomach and duodenum. The foreign body was detected by palpating in the proximal line of the duodenum (Figure 3a). During the operation, the duodenum was observed to hemorrhagic and edematous, and the excised serrated foreign body was photographed (Figure 3a, b).

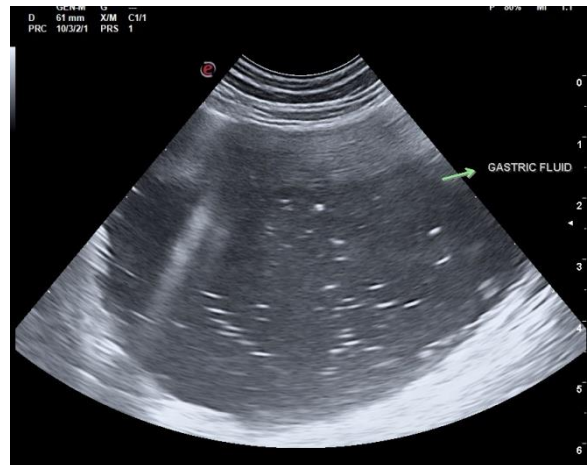
In the postoperative period, feeding was limited for two days. Amoxicillin and clavulanic acid (Synulox, Pfizer, USA, daily 0,4 ml SC for five days ) and enrofloxacin (Baytril, Bayer, Germany, daily 0,4 ml SC for five days) antibiotic combinations were used. Ulcuran (ranitidine, 1 mg/kg IV every 12 hours for five days), carprofen (Rymadyl, Zoetis, USA, daily 0,3 ml SC for five days), amino acids, vitamin B complex, electrolytes, and dextrose (Duphalayt, Zoetis) were applied via the intravenous and subcutaneous routes. Fluid intake was started in second day of the treatment. A week later, the patient was sent to the home from the veterinary clinic. A complete recovery was achieved. After postoperative treatment food intake was limited in the first two days. Amoxicillin and Clavulanic Acid

(Synulox ; Pfizer) and enrofloxacin (Baytril; Bayer) antibiotics were used in combination. Ulcuran (3.5 mg / kg twice daily), carprofen (Rymadyl; Zoetis), Amino acids, vitamin B complex, Electrolytes and dextrose (Duphalayt zoetis) were applied. Liquid

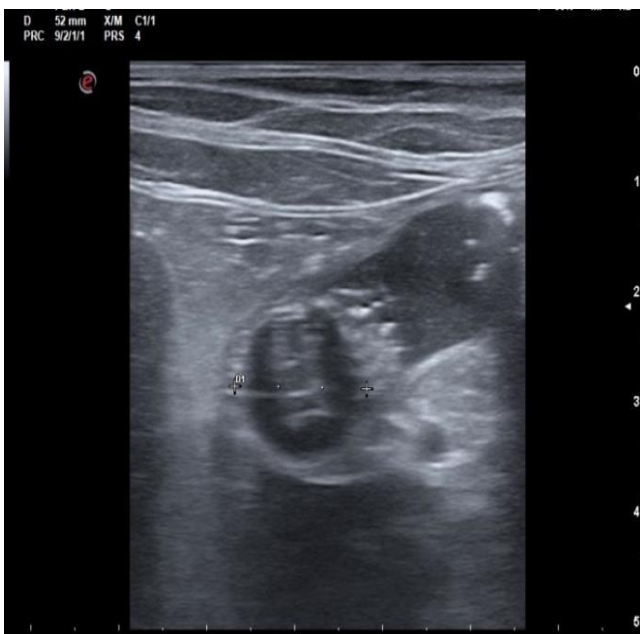food was started at the end of the second day of the treatment. One week later, the patient was discharged from veterinary clinic. A complete recovery was achieved.



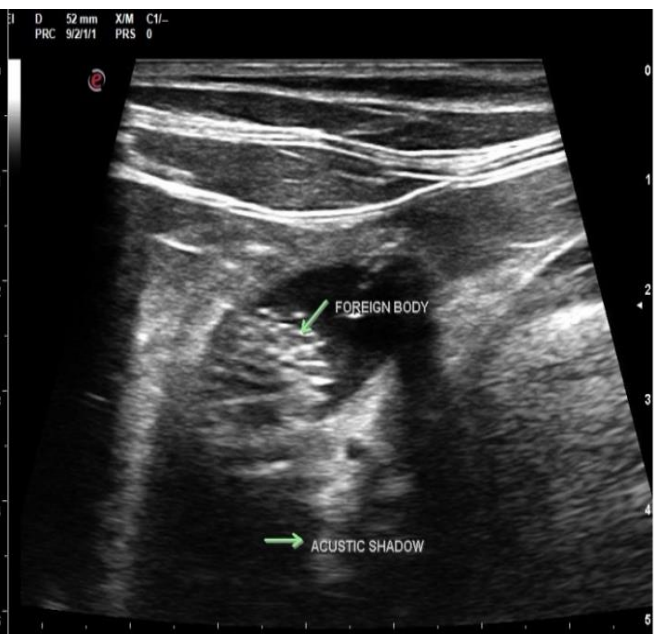**Figure 1a.** Monitoring the dense crystal in urinary bladder



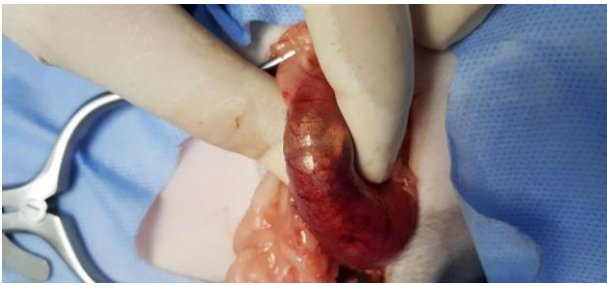**Figure 1b.** The fundus of the stomach is quite enlarged and tense with dense fluid content



**Figure 2a.** Oval foreign body with a hypoechoic surface and anechoic center.



**Figure 2b.** A large number of hyperechoic areas resembling a jagged structure can be easily selected in ultrasound sections towards the outer surface of the foreign body. Liquid accumulation in the area behind the obstruction is remarkable.



**Figure 3a.** During the operation, the foreign body was palpated with the hemorrhagic and edematous appearance of duodenum



**Figure 3b.** Serrated foreign body

**Table 1.** The hemogram parameters of the patient.

Analyte (units)	Reference interval	Admission	Follow up 5 months later
WBC ( $\times 10^9/l$ )	5,5-19,5	13,3	9,7
PLT ( $\times 10^9/l$ )	300-700	133	293
Hemoglobin (mmol/l)	8-15	20	13,4
HCT (mmol/l)	30-45	55,5	40,9
Sodium (mmol/l)	150-165	129	158
Potassium (mmol/l)	3,5-5,8	2,1	4,2
Chloride (mmol/l)	112-129	80	117
Glucose (mmol/l)	4,11-8,83	18,78	7,55
Urea (mmol/l)	5,71-12,85	32,14	8,43
Creatinine (mmol/l)	70,72-212,16	188,24	110,50
Total Protein (g/l)	57-89	75	69
Albumin (g/l)	22-40	28	32
ALT (IU/l)	5-130	119	78
AST (IU/l)	0-48	57	33

## Discussion and Conclusion

Many studies have reported that hypochloremic metabolic alkalosis may occur in proximal gastrointestinal obstructions caused by foreign bodies (Boag ve ark., 2005). In an experimental

study of dogs, it was reported that potassium and sodium secretion were proximal to the occlusion of the ileum. As a result of the secretion, many fluids and electrolytes were retained in the gastrointestinal lumen (Shields, 1965). Gastric fluid contains abundant chloride, sodium, and potassium. Loss of these fluids and electrolytes could cause metabolic alkalosis (Boag ve ark., 2005; Jukes ve ark., 2017). Moreover, 87% of the instances of metabolic alkalosis in cats have hypochloremic properties (Ha ve ark., 2013). In one study, it was reported that hypochloremic metabolic alkalosis due to gastrointestinal obstruction in cats caused fasciculation and tremors. Another case report was the first to show fasciculation and tremors caused by hypochloremic metabolic alkalosis due to duodenal obstruction (Jukes ve ark. 2017). In the present study, duodenal obstruction caused by a foreign body was detected by ultrasonographic examination. Abundant fluid accumulation behind the obstruction was observed. Serum potassium and chloride levels had declined because of an accumulation of fluid and electrolytes in the lumen and because of vomiting. In our case, hypochloremic metabolic alkalosis was also thought to have occurred.

In this case, gastrointestinal obstruction rather than a neurological origin was suspected at first because of fasciculation, tremor, abdominal swelling, and tenderness with severe vomiting (although fasciculation and tremor may also originate neurologically). It was thought that neuromuscular symptoms had improved with a significant increase in electrolyte levels and that neurological clinical findings had been caused by electrolyte abnormalities, especially hypokalemia caused by duodenal obstruction.

Foreign bodies may be found incidentally and, depending on the location of those foreign bodies, may cause various clinical symptoms in a patient. If the foreign body is radiopaque, it can be diagnosed by radiography. But if the foreign body has radioactive properties that are masked by the content or liquid, other methods, such as using air or barium, may be required to identify the foreign body. If the exact location of a radiopaque foreign body in the gastrointestinal tract remains uncertain after radiography, further study may be needed to determine an appropriate identification (Tidwell ve Pennick, 1992). Foreign bodies in the stomach and intestines may be identified by using ultrasonography. Ultrasonography has been reported to be very useful and effective in detecting gastrointestinal foreign bodies (Bebchuk, 2002; Winter ve ark., 2017). Many foreign bodies exhibit a characteristic ultrasonographic appearance

because of their tendency to transmit or attenuate sound waves. The presence of a shiny boundary surface with a strong shadow typically indicates a foreign body (Tidwell ve Pennick, 1992; Koenhemssi ve ark., 2011). Foreign plastic bodies may exhibit different ultrasonographic properties (Figures 2a-2b). Because of the way the body absorbs sound waves during an ultrasonographic examination, the semicircular echogenic surface may exhibit many different appearances, but not limited to acoustical shading or lack of shading, homogeneity, roundness, anechoic centering, and side shading. The plastic foreign body that we detected was similar to the one detected by Tidwell ve Pennick (1992), i.e., round echogenic. The center was generally anechoic with acoustic shadowing. In contrast, an irregular oval hyperechoic area with a small number of contours was observed on the outer surface of this object. These contours resembled those of an object with a serrated outer surface. This ultrasonographic image facilitated predictions about the object during diagnosis.

According to one study, ultrasonography is insufficient for imaging foreign bodies in the stomach because of the gas content (Özgermen ve ark., 2016). But in an another study, 14 cases of foreign bodies that could not be detected by radiography were detected by ultrasonography, and seven of these foreign bodies were in the stomach (Tidwell ve Pennick, 1992). In a different study, 52% of mechanical obstructions were detected by radiography, and 96% were correctly diagnosed by ultrasonography (Sharma 2010). It has also been reported that ultrasonography was the only imaging method that could be used in the diagnosis of gastrointestinal foreign bodies (Tyrrell ve Beck, 2006). In this study, 100% of foreign bodies were found by ultrasonography.

In our case, the diagnosis was quickly made by ultrasonography without using radiographic imaging. Detailed information was obtained about the shape and structure of the foreign body. The diagnosis was confirmed by information from the patient. Detailed information about the anatomical location of the body and the current status of the surrounding intestinal tissues was also obtained. As a result, the operation could be done more quickly and reliably than it could have been without ultrasonography.

Ultrasonographic examination is a fast and reliable diagnostic method that enables noninvasive and rapid application in cases of suspected gastrointestinal obstructions by foreign bodies.

Other findings such as acute pancreatitis, peritoneal fluids, mechanical obstructions, and benign or malign gastrointestinal masses can also be examined

in detail by ultrasonography. In addition, ultrasonographic examination provides more detailed information than radiographic imaging does about the anatomical location of foreign bodies prior to surgery. Because of the advantages of ultrasonographic examination, it may be preferred as the primary diagnostic method for detecting gastrointestinal foreign bodies.

### **Conflict of interest**

The authors declare that they have no conflict of interest.

### **References**

- Aronson LR**, Brockman DJ, Brown DC (2000) Gastrointestinal emergencies. *Veterinary Clinics of North America: Small Animal Practice*. 30(3): 555-579
- Bebchuk TN** (2002) Feline gastrointestinal foreign bodies. *Vet Clin Small Anim* 32: 861-880. [https://doi.org/10.1016/s0195-5616\(02\)00030-x](https://doi.org/10.1016/s0195-5616(02)00030-x).
- Boag AK**, Coe RJ, Martinez TA, Hughes D (2005) Acid-base and electrolyte abnormalities in dogs with gastrointestinal foreign bodies. *J Vet Intern Med*; 19: 816-821. [https://doi.org/10.1892/08916640\(2005\)19\[816:aaeaid\]2.0.co;2](https://doi.org/10.1892/08916640(2005)19[816:aaeaid]2.0.co;2)
- Ellison GW** (1998) Intersinal obstruction. In: Bojrab MJ (ed). *Disease Mechanisms in Small Animal Surgery*. Philadelphia USA pp 252-257.
- Ha YS**, Hopper K and Epstein SE (2013) Incidence, nature, and etiology of metabolic alkalosis in dogs and cats. *J Vet Intern Med*; 4: 847-853. <https://doi.org/10.1111/jvim.12122>
- Jukes A**, Gunew M, Marshall R (2017) Severe muscle fasciculations and tremor in a cat with hypochloremic metabolic alkalosis secondary to duodenal obstruction. *JFMS Open Reports* 1-4. <https://doi.org/10.1177/2055116916686427>
- Koenhemssi L**, Iskefli O, Dokuzeylül B, et al. Radiologic and ultrasonographic examination of a dog with acute gastric dilatation due to foreign body [abstract]. *Van Vet J*; 3: 185-187.
- Ozgermen BB**, Sen Y, Unal E, et al. (2011) Clinical, radiographic and ultrasonographic evaluation of gastric diseases in dogs [abstract]. *Turk J Vet Med Soc* 2016; 2: 44-57.
- Papazoglou LG**, Patikas MN, Rallis T (2003) Intestinal foreign bodies in dogs and cats. *Comp Cont Educ Pract*; 25: 830,843.
- Sharma A**, Thompson MS, Scrivani PV et al. (2011) Comparison of radiography and ultrasonography for diagnosing small-intestinal mechanical obstruction in vomiting dogs. *Vet Radiol Ultrasound*; 3: 248-255. <https://doi.org/10.1111/j.1740-8261.2010.01791.x>
- Shields R** (1965) The absorption and secretion of fluid and electrolytes by the obstructed bowel. *Br J Surg*; 10: 774-779. <https://doi.org/10.1002/bjs.1800521019>

**Tidwell** AS, Pennick DG (1992) Ultrasonography of gastrointestinal foreign bodies. *Vet Radiol Ultrasound*; 3:160-169. <https://doi.org/10.1111/j.1740-8261.1992.tb01439.x>

**Tyrrell** D, Beck C (2006) Survey of the use of radiography vs. ultrasonography in the investigation of gastrointestinal foreign bodies in small animals. *Vet Radiol Ultrasound*; 4:404–408. <https://doi.org/10.1111/j.1740-8261.2006.00160.x>

**Winter** DM, Barry KS, Johson MD, et all. (2017) Ultrasonographic and computed tomographic characterization and localization of suspected mechanical gastrointestinal obstruction in dogs. *J Am Vet med Assoc*; 3: 315-321. <https://doi.org/10.2460/javma.251.3.315>