



The Effect of Croton-Oil-Induced Experimental Hemorrhoid Model on Testicular Histology and Some Sperm Parameters

Volkan Koşal^{1,a,*}, Halil Cumhur Yılmaz^{2,b}

¹Department of Artificial Insemination, Faculty of Veterinary Medicine, Van Yuzuncu Yıl University, Van, Türkiye

²Department of Histology and Embriology, Faculty of Veterinary Medicine, Van Yuzuncu Yıl University, Van, Türkiye

*Corresponding author

Research Article

History

Received: 03/06/2025

Accepted: 20/06/2025

ABSTRACT

It was aimed to investigate the effects of Croton oil obtained from the Croton Tiglium plant on testicular histology and sperm parameters in male rats in an experimental hemorrhoid model caused by rectal administration. Sixteen male Albino Wistar rats were used for the experimental study. The animals were randomly divided into 2 groups. No treatment was applied to the control group (n=8). In the Croton oil group (n:8), a hemorrhoid model was created by applying Croton oil into the rectum with the help of a swab. The rats were sacrificed after 5 days. After sacrifice, testicular tissue samples were fixed with 10% neutral buffered formalin and Bouin's fixative solution for histologic examination. Motility, concentration, and abnormal sperm rates were determined in sperm samples obtained by puncture of the cauda epididymis. Histologically, it was observed that the lumens of the capillaries between the seminiferous tubules were enlarged in the Croton oil treated group, but there was no change in spermatogenic cells, Sertoli cells, and Leydig cells. In sperm analysis, no statistically significant difference was found in motility rate, concentration, and abnormal sperm rates ($p>0.05$). It was determined that local venous inflammation caused by Croton oil in the rectal area may have partial effects on the venous structures in the testis, but did not cause any change in sperm parameters.

Keywords: Croton oil, Hemorroid model, Sperm, Testis.

Kroton-Yağıyla Oluşturulan Deneysel Hemoroid Modelinin Testis Histolojisi ve Bazı Sperm Parametreleri Üzerine Etkisi

Süreç

Geliş: 03/06/2025

Kabul: 20/06/2025

Copyright



This work is licensed under
Creative Commons Attribution
4.0 International License

Öz

Croton tiglium bitkisinden elde edilen kroton yağının rektal uygulama ile oluşturulan deneyisel hemoroid modelinde erkek sıçanlarda testis histolojisi ve sperm parametreleri üzerine etkilerinin araştırılması amaçlanmıştır. Deneyisel çalışma için 16 erkek Albino Wistar sıçan kullanıldı. Hayvanlar rastgele 2 gruba ayrılmıştır. Kontrol grubuna hiçbir tedavi uygulanmadı (n:8). Kroton yağı grubunda (n:8), kroton yağı rektum içine swap yardımıyla uygulanarak hemoroid modeli oluşturuldu. Sıçanlar 5 gün sonra sakrifiye edildi. Sakrifikasyondan sonra histolojik inceleme için testis doku örnekleri %10'luk nötral tamponlu formalin ve Bouin tespit solüsyonu ile tespit edildi. Kauda epididimis punksiyonu ile elde edilen sperm örneklerinde motilite, yoğunluk ve anormal sperm oranları belirlendi. Histolojik olarak, kroton yağı uygulanan grupta seminifer tübüller arasındaki kapillerlerin lümenlerinin genişlediği, ancak spermatojenik hücreler, Sertoli hücreleri ve Leydig hücrelerinde herhangi bir değişiklik olmadığı gözlemlendi. Sperm analizinde motilite oranı, yoğunluk ve anormal sperm oranlarında istatistiksel olarak anlamlı bir fark bulunmamıştır ($p>0.05$). Kroton yağının rektal bölgede neden olduğu lokal venöz inflamasyonun testisteki venöz yapılar üzerinde kısmi etkileri olabileceği, ancak sperm parametrelerinde herhangi bir değişikliği neden olmadığı belirlendi.

Anahtar Kelimeler: Kroton yağı, Hemoroid model, Sperm, Testis.

^a Mail: volkankosal@yyu.edu.tr

^b ORCID: 0000-0001-5268-5046

^b Mail: halilcumhuryilmaz@yyu.edu.tr ^b ORCID: 0000-0003-3958-7948

How to Cite: Kosal V, Yılmaz HC (2025) The Effect of Croton-Oil-Induced Experimental Hemorrhoid Model on Testicular Histology and Some Sperm Parameters, Turkish Veterinary Journal, 7(1): 1-5

Introduction

Croton tiglium L. (Euphorbiaceae) is a plant species that grows widely in tropical and temperate climatic zones and has long been used in traditional medicine to treat various diseases (Antonio et al., 2007). Different parts of the plant, such as leaves, bark, roots, and seeds, are used in the treatment of many diseases. Croton tiglium is traditionally preferred for

the treatment of gastrointestinal disorders, rheumatism, ulcers, headache, fever, parasitic infections, and snake envenomation (Antonio et al., 2007; Campos et al., 2002). Croton oil contains biologically active components such as phorbol esters, crotonic acid and various fatty acids (Wang et al., 2002).

Studies have revealed that *C. tiglium* extract inhibits cell growth in some cancer types by showing antiproliferative effects (Song et al., 2017). In addition, its ethanolic extract has been reported to have significant antifungal activity against dermatophyte fungi such as *Trichophyton mentagrophytes*, *T. rubrum*, and *Epidermophyton floccosum* (Tsai et al., 2004). Especially the seeds, due to the Croton oil they contain, show a strong laxative effect and also have toxic properties (Saputera et al., 2008). These properties of the plant support its pharmaceutical potential and provide a solid basis for scientific research.

Croton oil is widely used to induce hemorrhoids in experimental animal models. Croton oil triggers local inflammation, causing hyperemia, edema and hemorrhoidal-like swelling of the anal mucosa (Nallajerla & Ganta 2023). In recent years, a common connective tissue weakness and venous wall changes have been suggested between hemorrhoidal disease and systemic venous pathologies, especially varicocele (Pasqualotto et al., 2003; Taşkın et al., 2024). Hemorrhoids are characterized by abnormal dilatation and displacement of the anal venous plexus. Pathophysiologically, hemorrhoids have common features with other venous diseases such as varicocele (Yetkin & İleri, 2016; Sun et al., 2018). Venous insufficiency, inflammation, connective tissue weakness, and mechanical strain are thought to play a role in the pathophysiology of hemorrhoids. In the literature, it is still not fully clarified whether regional pathologies in the venous system affect distant organs. Especially, the effects of local venous inflammation on spermatogenesis and testicular microcirculation are unknown.

In the present study, we aimed to investigate the short-term effects of an experimental hemorrhoid model induced by Croton oil on testicular tissue histology and sperm parameters. This study is thought to contribute to the lack of knowledge about the distant organ effects of venous system pathologies.

Materials and Methods

Animal experiments were performed at Van Yüzüncü Yıl University Experimental Medicine Application and Research Centre with the approval of the local ethics committee (Decision no: 2025/06-10 Date:29/05/2025). The rats were kept at a room temperature of 22-24 °C with 12 hours of light and 12 hours of dark, 55-60% humidity. They were fed ad libitum with pellet feed.

Experimental groups and induction of hemorrhoids

The experimental groups were formed with 8 male rats in each group, as a control and a hemorrhoid group. Rats in the hemorrhoid group were fasted overnight, and hemorrhoids were induced with Croton oil (Azeemuddin et al., 2014). Croton oil solution (a mixture of deionized water, pyridine, diethyl ether and

6% Croton oil in diethyl ether - ratios = 1: 4: 5: 10, respectively) was applied into the anal opening (rectoanal portion, 20 mm from anal opening) with a cotton swab. The swab was kept in the anal opening for 1 min and then observed. Edema formation was observed in the area in rats within 6-7 hours.

Experimentation and sample collection

After 5 days of follow-up, feeding, and care, the rats were anesthetized (xylazine/ketamine) on the 6th day, and the animals were euthanized (Sancak, 2023); tissue samples were taken. Testicular tissue samples were fixed with two different fixation solutions. Tissue samples fixed with 10% neutral buffered formalin and Bouin (Layton et al., 2019) were processed by routine histological method, and paraffin blocks were prepared (in Bouin fixation, washing was performed with 70% ethyl alcohol for 12 hours). Sections (6 µm) taken from the tissue blocks with a microtome (Leica RM-2135) were stained with the Crossman modification of Mallory triple stain (Erbaş et al., 2024). Spermatogenic cells and connective tissue, and their parts, were examined histologically. Photographs were taken under a microscope (Zeiss Lab A1- AxioCam).

Spermatological Analysis

Motility examination: Sperm sample was obtained by epididymis puncture immediately after the rats were sacrificed and placed on a slide on a heating table set at 38°C. The coverslip was closed at a 45° angle, and motility (in %) was determined by microscopy at X40 magnification.

Sperm concentration

After epididymal puncture, a 0.1 ml sperm sample was added to Eppendorf tubes containing 0.5 ml Hayem's solution. Sperm count per mL was calculated using a Thoma cell counting chamber.

Abnormal sperm rate

Semen obtained by epididymal puncture was transferred into Eppendorf tubes containing 0.5 ml Hancock solution. At least 400 sperm cells were examined at X40 magnification to determine the ratio.

Statistical Analysis

SPSS v.20 (Chicago, IL, USA) package program was used for statistical analysis. All data were expressed as mean ± standard deviation. Statistical analyses of the groups were statistically analyzed using One-Way ANOVA, followed by post hoc multiple comparisons (Tukey test) for comparative analysis between groups. P<0.05 was considered statistically significant.

Results and Discussion

Crotonic acid, crotonoleic acid, and several other fatty acids are toxic chemicals that restrict the potential therapeutic use of Croton tiglium. Its seeds contain this toxalbumin, which inhibits protein synthesis by disabling ribosomes, causing hemolysis and cell destruction. This is because the seed oil contains phorbol esters and crotonic acid along with fatty acids,

in addition to the presence of active phytoconstituents (Stirpe et al., 1976; Zhang et al., 2015).

The appearance of spermatogenic cells, Sertoli cells, and Leydig cells was normal in both fixation solutions and both experimental groups. Tubulus seminiferous contortus (TSC) lumens were filled with spermatozoa,

and connective tissue structures were observed properly. Microscopic examinations showed that the lumens of the capillaries located close to the Leydig cells in the group with Croton oil were relatively enlarged (Figure 1).

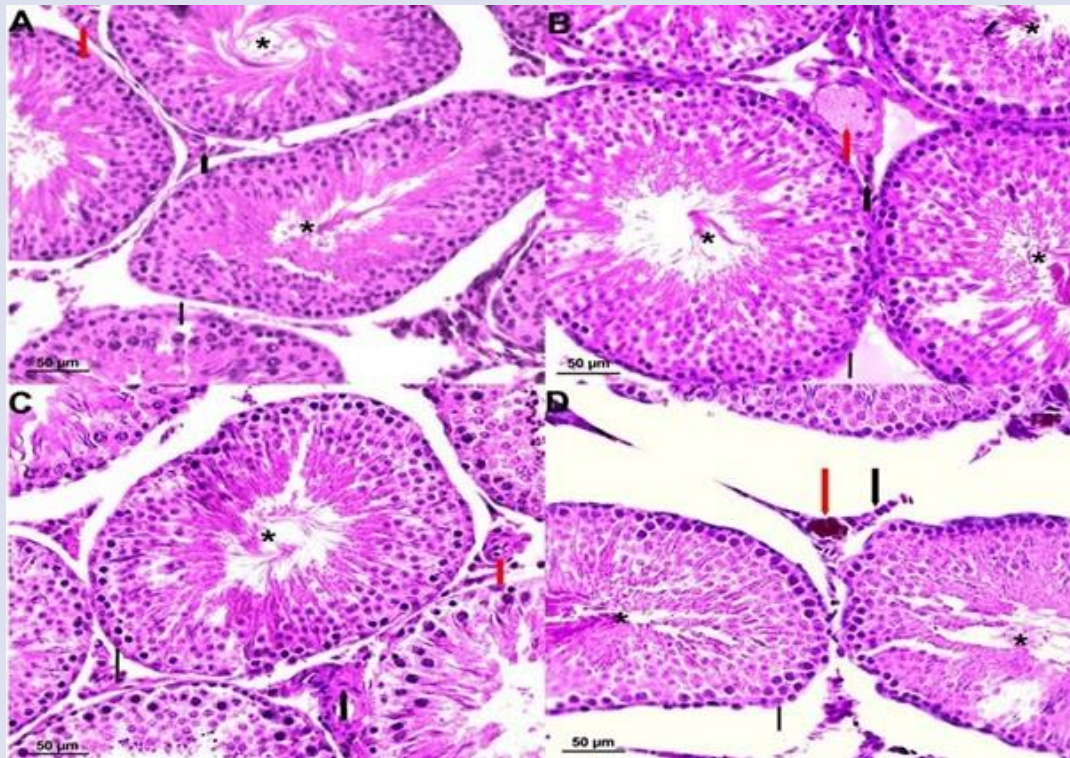


Figure 1. A: Bouin-Control, B: Bouin-hemorrhoid, C: Bouin-Kontrol, D: Formol-hemorrhoid. *=TSC lumens, Red thick arrows = capillaries, Black thick arrow= Leydig cells, Black thin arrow= Sertoli cells.

The overall structural integrity of the venous system may be affected by regional events such as anal inflammation. Studies have revealed the relationship between hemorrhoids and varicocele. It has been shown that venous hypertension and venous valve insufficiency play an important role in the pathogenesis of these diseases (Chen et al., 2022; Taşkın et al., 2024). In the present study, no differences were found in spermatogenic cells, Sertoli cells, and Leydig cells in the histopathologic examination of the testis in the group using Croton oil, but capillary vessels between the TSC were found to be enlarged. The observation of capillary dilatation between the TSCs suggests that Croton oil administered rectally also acts in the uro-genital region and causes vasodilation.

Studies examining the male reproductive system using Croton oil are limited in the literature. It is reported that Croton oil is used in traditional Chinese medicine and African countries to increase male reproductive parameters. In addition, Croton oil has toxic effects (Rampa et al., 2022; Junior et al., 2022; Isyaka et al., 2024; Sun et al., 2024). In the present study, no difference was observed in sperm motility, concentration, and abnormal sperm rates in the Croton oil group compared to the control group (Table 1). The

difference between the studies examining the effects of Croton oil on the male reproductive system is thought to be due to the route of administration, duration of administration, and the use of different croton species (Croton membranaceus, Croton cajucara, Croton zambesicus) (Ofusori et al., 2007; Caneguim et al., 2011; Afriyie et al., 2014).

Table 1. Epididymal sperm analysis.

	Control	Croton oil	p
Motility (%)	80.55±5.87 ^a	78.45±6.8 ^a	>0.05
Concentration (×10⁹)	2.04±0.09 ^a	1.96±0.13 ^a	>0.05
Abnormal (%)	16.54±1.98 ^a	16.14±0.77 ^a	>0.05

As a result of sperm analysis, no statistically significant difference was found between the control and Croton oil groups in terms of sperm motility, concentration, and abnormal sperm rates (p>0.05).

Conclusion

In an experimental hemorrhoid model induced with Croton oil, mild histopathological changes, such as lumens of the capillaries relatively enlarged in the testes. However, no significant inflammation or impaired spermatogenesis was observed. These

findings suggest that local inflammation in the anal region does not directly cause serious damage to the testicular tissue but may lead to mild changes in the systemic venous circulation. This study supports that local inflammatory processes may have effects on venous structures in distant organs, and future studies need to evaluate the long-term consequences of these effects and their possible reflections on fertility.

Conflict of Interest

The authors declared that there is no conflict of interest.

References

- Afriyie, D. K., Asare, G. A., Bugyei, K., Adjei, S., Lin, J. M., Peng, J., & Hong, Z. F. (2014). Treatment of benign prostatic hyperplasia with *Croton membranaceus* in an experimental animal model. *Journal of Ethnopharmacology*, 157, 90-98. <https://doi.org/10.1016/j.jep.2014.09.007>
- Antonio, S., Maria, L. F. S., & Giuseppina, N. (2007). Traditional uses, chemistry, and pharmacology of *Croton* species (Euphorbiaceae). *Journal of the Brazilian Chemical Society*, 18, 11-33. <https://doi.org/10.1590/S0103-50532007000100002>
- Azeemuddin, M., Viswanatha, G. L., Rafiq, M., Thippeswamy, A. H., Baig, M. R., Kavya, K. J., Patki, P. S., & Shyam, R. (2014). An improved experimental model of hemorrhoids in rats: evaluation of antihemorrhoidal activity of an herbal formulation. *International Scholarly Research Notices*, 2014(1), 530931. <https://doi.org/10.1155/2014/530931>
- Campos, A. R., Albuquerque, F. A., Rao, V. S., Maciel, M. A., & Pinto, A. C. (2002). Investigations on the antinociceptive activity of crude extracts from *Croton cajucara* leaves in mice. *Fitoterapia*, 73, 116-120. [https://doi.org/10.1016/S0367-326X\(02\)00004-7](https://doi.org/10.1016/S0367-326X(02)00004-7)
- Caneguim, B. H., Serpeloni, J. M., Maciel, M. A. M., de Syllos Cólus, I. M., & de Fatima Paccola Mesquita, S. (2011). Reduction of DNA-damage by *croton cajucara* methanolic extract, but not the testicular alterations induced by doxorubicin. *J Med Plants Res*, 5, 3277-3285. <https://doi.org/10.5897/JMPR.9000416>
- Chen, D., Luo, Q., Fan, W., Chen, C., & Liu, G. (2022). The association between varicocele and other vascular diseases: A systematic review and meta-analysis. *Phlebology*, 37(4), 233-240. <https://doi.org/10.1177/02683555211069247>
- Erbas, E., Üstündağ, H., Öztürk, E., Parlak, S. N., & Atcalı, T. (2024). Astaxanthin treatment reduces kidney damage and facilitates antioxidant recovery in lithium-intoxicated rats. *Toxicol*, 241, 107664. <https://doi.org/10.1016/j.toxicol.2024.107664>
- Iyaka, S. M., Akintayo, A. H., & Abdullahi, A. M. (2024). A Review of Ethnomedicinal Uses, Phytochemistry and Pharmacology of Nigerian *Crotons*. *Archives of Current Research International*, 24(12), 250-274. <https://doi.org/10.9734/acri/2024/v24i121016>
- Junior, J. I. G., Ferreira, M. R. A., de Oliveira, A. M., & Soares, L. A. L. (2022). *Croton* sp.: a review about popular uses, biological activities, and chemical composition. *Research, Society and Development*, 11(2), e57311225306-e57311225306. <https://doi.org/10.33448/rsd-v11i2.25306>
- Layton, C., Bancroft, J. D. & Suvarna, S. K. (2019). Bancroft's theory and practice of histological techniques. Layton, C., Bancroft, J. D. & Suvarna, S. K. (Eds), *Fixation of tissues* (p.p.=40-63), Elsevier.
- Nallajerla, S. K., & Ganta, S. (2023). *Croton* Oil-induced Hemorrhoidal Rats: Evaluation of Anti-inflammatory Mediated Anti-hemorrhoidal Activity of Tridax procumbens Whole Plant. *Current Bioactive Compounds*, 19(7), 17-28. <https://doi.org/10.2174/1573407219666230207105946>
- Ofusori, D. A., Oluwayinka, O. P., Adelakun, A. E., Keji, S. T., Oluyemi, K. A., Adesanya, O. A., Ajeigbe K. O., & Ayoka, A. O. (2007). Evaluation of the effect of ethanolic extract of *Croton zambesicus* on the testes of Swiss albino mice. *African Journal of Biotechnology*, 6(21), 2434-2438. <https://doi.org/10.5897/AJB2007.000-2383>
- Pasqualotto, F. F., Lucon, A. M., Hallak, J., Góes, P. M., Saldanha, L. B., & Arap, S. (2003). Induction of spermatogenesis in azoospermic men after varicocele repair. *Human Reproduction*, 18(1), 108-112. <https://doi.org/10.1093/humrep/deg032>
- Rampa, K. M., Van De Venter, M., Koekemoer, T. C., Swanepoel, B., Venables, L., Hattingh, A. C., Viljoen, A. M., & Kamatou, G. P. (2022). Exploring four South African *Croton* species for potential anti-inflammatory properties: In vitro activity and toxicity risk assessment. *Journal of Ethnopharmacology*, 282, 114596. <https://doi.org/10.1016/j.jep.2021.114596>
- Sancak, T. (2023). The effects of repeated doses of xylazine-ketamine and medetomidineketamine anesthesia on DNA damage in the liver and kidney. *Acta Cirurgica Brasileira*, 38, e385723. <https://doi.org/10.1590/acb385723>
- Saputera, Mangunwidjaja, D., Raharja, S., Kardono, L. B. S., & Iswantini, D. (2008). Characteristics, efficacy, and safety testing of standardized extract of *Croton tiglium* seed from Indonesia as laxative material. *Pakistan Journal of Biological Sciences*, 11, 618-622. <https://doi.org/10.3923/pjbs.2008.618.622>
- Song, H. K., Lee, G. S., Park, S. H., Noh, E. M., Kim, J. M., Ryu, D. G., Jung, S. H., Youn, H. J., Lee, Y. R., & Kwon, K. B. (2017). *Crotonis Fructus* extract inhibits 12-O-Tetradecanoylphorbol-13-acetate-induced expression of matrix Metalloproteinase-9 via the activator protein-1 pathway in MCF-7 cells. *Journal of Breast Cancer*, 20, 234-239. <https://doi.org/10.4048/jbc.2017.20.3.234>
- Stirpe, F., Pession-Brizzi, A., Lorenzoni, E., Strocchi, P., Montanaro, L., & Sperti, S. (1976). Studies on the proteins from the seeds of *Croton tiglium* and of *Jatropha curcas*. Toxic properties and inhibition of

- protein synthesis in vitro. *Biochemical Journal*, 156(1), 1-6. <https://doi.org/10.1042/bj1560001>
- Sun, C., Wu, W., Yin, Z., Fan, L., Ma, Y., Lai, F., & Wu, H. (2018). Effects of simulated gastrointestinal digestion on the physicochemical properties, erythrocyte haemolysis inhibitory ability, and chemical antioxidant activity of mulberry leaf protein and its hydrolysates. *International Journal of Food Science & Technology*, 53, 282-295. <https://doi.org/10.1111/ijfs.13584>
- Sun, M., Zeng, W., & Zhao, Z. (2024). *Croton crassifolius* Geisel. A comprehensive review of the botany, traditional uses, phytochemistry, pharmacology, and quality control. *Journal of Ethnopharmacology*, 320, 117352. <https://doi.org/10.1016/j.jep.2023.117352>
- Taşkın, A. K., Gül, A., & Kat, N. (2024). Evaluation of the possible relationship between hemorrhoidal disease and varicocele in adult men. *Cukurova Medical Journal*, 49(2), 439-445. <https://doi.org/10.17826/cumj.1463901>
- Tsai, J. C., Tsai, S., & Chang, W. C. (2004). Effect of ethanol extracts of three Chinese medicinal plants with laxative properties on ion transport of the rat intestinal epithelia. *Biological and Pharmaceutical Bulletin*, 27, 162-165. <https://doi.org/10.1248/bpb.27.162>
- Wang, X., Lan, M., Wu, H. P., Shi, Y. Q., Lu, J., Ding, J., Wu, K. C., Jin, J. P., & Fan, D. M. (2002). Direct effect of croton oil on intestinal epithelial cells and colonic smooth muscle cells. *World Journal of Gastroenterology*, 8, 103-107. <https://doi.org/10.3748/wjg.v8.i1.103>
- Yetkin, E., & Ileri, M. (2016). Dilating venous disease: pathophysiology and a systematic aspect to different vascular territories. *Medical Hypotheses*, 91, 73-76. <https://doi.org/10.1016/j.mehy.2016.04.016>
- Zhang, D. D., Zhou, B., Yu, J. H., Xu, C. H., Ding, J., Zhang, H., & Yue, J. M. (2015). Cytotoxic tiglane-type diterpenoids from *Croton tiglium*. *Tetrahedron*, 71(52), 9638-9644. <https://doi.org/10.1016/j.tet.2015.10.070>