



Treatment of Tibial Fractures with the Use of Interlocking Nail and Acrylic External Fixator Combination in Dogs

Ilker SEN

Sivas Cumhuriyet University, Faculty of Veterinary Medicine, Department of Surgery, Sivas, Turkey

SEN I 0000-0001-8288-4871

*Corresponding Author's E-Mail: ilkersenn@yandex.com

Abstract

In this study, a combination of interlocking nailing and uniplanar bilateral acrylic external fixators has been used in the treatment of dogs with diaphyseal tibial fractures. Via this method, it is both aimed to prevent possible implant failures due to the potential of high stress accumulation in the distal and proximal parts because of the design of interlocking pins and also is aimed to reduce the risk of functional recovery losses due to instability caused by torsional and bending forces because of weight bearing in the postoperative period. The study material involves 6 dogs. Each case was treated using 6 mm interlocking pins of various lengths and 2-2.5 mm half and full Steinmann pins. Radiographs were taken on the postoperative 10th, 30th, 45th days and clinical follow-up period was ended on 45th day. However, postoperative follow-up period of case no 5 has continued until day 58 due to infection. As an alternative to intramedullary nailing, interlocking pins has resulted in success when combined with external fixators. Interlocking pin and acrylic external fixation combination technique can be considered as an alternative method as it prevents instability that can be caused by using only interlocking nailing, and as it provides a rapid healing.

Received 12 October 2019
Received in revised form 3 March 2020
Accepted 18 June 2020

Anahtar kelimeler:
Acrylic external fixator, interlocking nailing, tibia, osteosynthesis

Cite this article: Sen I (2020) Treatment of Tibial Fractures with the Use of Interlocking Nail and Acrylic External Fixator Combination in Dogs. Turk Vet J, 2(1):1-6.

Köpeklerde Karşılaşılan Tibia Kırıklarının Interlocking Pin ve Akrilik Eksternal Fiksator Kombinasyonu ile Sağaltımı

Özet

Bu çalışmada, köpeklerde meydana gelen diyafizer tibia kırıklarının sağaltımında interlocking pin ve uniplanar bilateral akrilik eksternal fiksatorların kombinasyonu kullanılarak, interlocking pinlerin dizaynından dolayı, pinin distal ve proksimalinde yüksek stres biriktirme potansiyelinden dolayı oluşması muhtemel implant hatalarının önüne geçmek ve postoperatif erken dönemde ilgili ekstremiteye ağırlık verilmesiyle oluşan torsiyonel ve bükülme kuvvetlerinin yol açtığı instabiliteye bağlı olarak fonksiyonel iyileşme kayıplarının oluşma riskini azaltmak amaçlandı. Çalışma materyalini, travma sonrası, ilgili arka ekstremitelerini kullanamama şikayetiyle getirilen, yapılan klinik ve radyolojik muayeneler sonrasında tibiasında kırık tespit edilen 6 köpek oluşturdu. Sağaltım için farklı uzunluklarda 6 mm çapında interlocking pinler, 2 ve 2,5 mm çapında yarım ve tam pin olarak Steinmann pinleri, akrilik ve içine enjekte edilip akriliğe şekil verebilmesi için 9 mm endotracheal tüpler kullanıldı. Postoperatif 10., 30., ve 45. günlerde radyografler alındı, klinik takip süreci 45. günde sona erdirildi. Ancak olgu no 5'in postoperatif takip süresi, gelişen enfeksiyondan dolayı, 58. güne kadar devam etti. İntramedullar pin uygulamalarına alternatif oluşturan interlocking pin ile sağaltım tekniği, eksternal fiksatorlarla kombine edilerek kullanıldığında başarılı sonuçlar vermiştir. Interlocking pin ve akrilik eksternal fiksator kombinasyonu ile sağaltım tekniği, interlocking pin ile sağaltım tekniğinin tek başına kullanılmasından dolayı oluşabilecek instabilitenin önüne geçilmesi ve iyileşmenin hızlı bir şekilde sağlanması açısından alternatif bir tedavi yöntemi olarak düşünülebilir.

Anahtar kelimeler: Akrilik eksternal fiksator, interlocking çivileme, tibia, osteosentez.

Introduction

Tibial fractures are frequently observed within dogs. These fractures have a rate of 20% among long bone fracture cases that are noticed in dogs. Approximately 73% of all tibial fractures are in the form of diaphyseal fractures (Van der Elst et al., 1999). Biological osteosynthesis methods are applied quite often in tibial fractures. The aim of biological osteosynthesis, particularly in segmental fractures of long bones, is to maintain mechanical

stability and a balanced preservation of the surrounding soft tissues. External fixator and interlocking nails can also be used in biological osteosynthesis applications (Goett et al., 2007; Piórek et al., 2012).

Interlocking nailing is an internal fixation method which is used especially in diaphyseal fractures of long bones. In this method, pin is placed to the medullary canal and fixed to the bone with screws

passing through proximal and distal holes which are placed on the pin (McLaughlin, 1999; Duhautois, 2003).

Interlocking pin stabilization technique has been used for rectification of angulations which are caused by the fractures of the bone in rotational and longitudinal direction in the treatment of comminuted and long spiral fractures and bone loss. It can be said that, when this technique is compared with conventional nonlocked intramedullary nailing methods, it reduced the risks of infection, non-union and malunion risks. In addition, it is also superior considering short hospitalization and rehabilitation periods (Bhat et al., 2006).

Interlocking pins are in various lengths and diameters. Their both ends have holes which the screws pass through. Ideally, the cortex of the affected bone should support two screws that will be applied both proximally and distally. The distance of the screws and fracture line should be at least 2 cm to prevent excessive force applied on the pin. The weakest feature of interlocking pins are the screw holes (Fossum, 2013).

Although interlocking nailing technique has the same indications as other intramedullary nailing techniques, it has a potential to accumulate high stress in proximal and distal parts due to the design of interlocking pins (Bhat et al., 2006).

Screw holes on the pin reduce the resistance of the pin. If screw holes are placed close to the fracture line, the possibility of fracture of the bone and the implant will emerge. If the screws are applied to the fracture line closer than 2 cm, stress will be observed (Stiffler, 2004).

In this technique which is used in fracture treatment, the pin can be broken if the diameter of the pin is not proper or if the screw holes on the pin are placed on the fracture line. Implant failures are frequently seen in proximal part of the distal pin holes. The most common complications related to the implant are, pin failure close to screw holes, misplacement of the screws or loose pin implementations (McLaughlin, 1999).

Interlocking nails can be implanted via minimal invasive surgical techniques; thus, it minimally damages the vascularization of operative area. In fact, it is reported that interlocking nailing has been considerably successful and has had low complication rates in many clinical studies. Although this technique is highly preferred by many surgeons because of its biological advantages, in some studies it has also been reported that it has both clinical and experimental limitations (Goett et al., 2007; Piórek et al., 2012).

Metal screws which are also used in interlocking nailing have minimal negative effects on the recovery process of fractures. However, it is possible to mention the disadvantages of such implants, such as bone atrophy, inflammatory or carcinogenic effects due to corrosion (Van der Elst et al., 1999; Bergsma et al., 1993; Bos et al., 1991).

In recent years, via in vivo model studies on sheep with tibial fractures where interlocking nails are compared to external fixators, some significant loss during recovery process has been noticed because of instability caused by torsional and bending forces among interlocking nailing groups (Goett et al., 2007; Piórek et al., 2012).

Since weight bearing during early postoperative period allows to increase stability in the fracture line, it brings some beneficial effects on healing. The combination of Interlocking nail and external fixator provides weight bearing (Piórek et al., 2012).

In this study, using a combination of interlocking pins and acrylic external fixators for the treatment of diaphyseal tibial fractures has served two purposes. The first purpose is to reduce complications such as stress fractures around at the level of screw holes in the operated bones. The second purpose is to reduce the risk of functional recovery losses caused by torsional and bending forces because of early weight bearing in postoperative period.

Material and Method

The study material involves 6 dogs which were admitted to the clinic with posttraumatic complaints of inability to use related hind limb with tibial fracture diagnosed via clinical and radiological examinations. While the reason of lesion in the 3 of 6 cases was a traffic accident, the reason could not be defined in the other in 3 cases. After clinical and radiological examinations, diaphyseal tibial fracture has been detected in all cases included in the study. Each case has been treated with 6 mm interlocking nails of various lengths, 2-2.5 mm half and full Steinmann pins, acrylic and 9 mm endotracheal tubes for preserving and shaping the acrylic.

Surgical procedure

Interlocking nailing has been practiced routinely, but instead of stabilizing the pin to the bone with screws through proximal and distal holes, half and full Steinmann pins were fixed to the bone by passing through the holes. The ends of the pins were then passed through steril 9 mm endotracheal tubes. Soft tissues were routinely closed, and then fluid acrylic was injected into empty endotracheal tubes and was expected to be solidified (Fig 1).

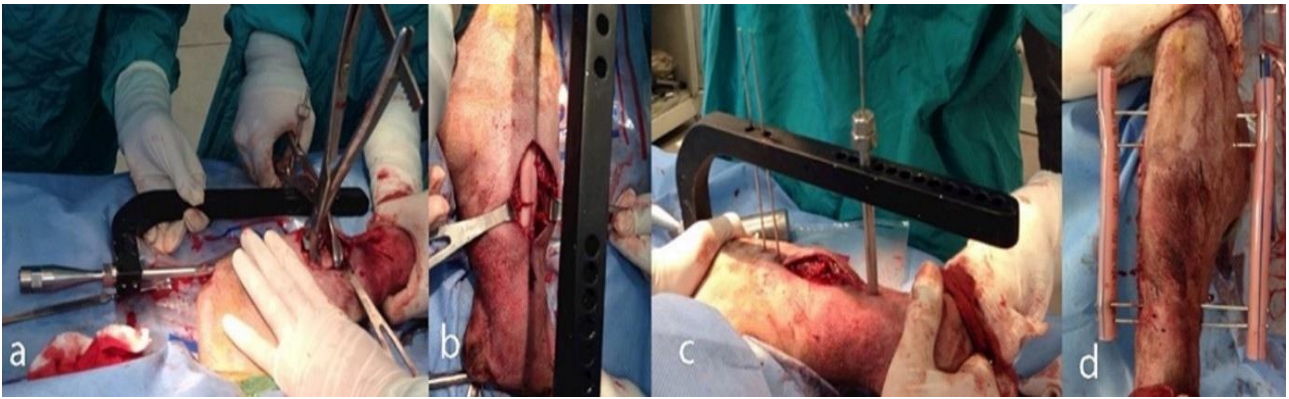


Figure 1. a and b. Standardt fixation of interlocking nail to tibia, c. application of Steinmann pin to the proximal and distal screw holes of the interlocking nail, d. combination of full Steinmann pins with acrylic.

Assessment

In order to define lameness degrees, each patient was scored from 0 to 4 on the 10th, 30th, 45th days of the follow-up period. The scale for the assessment of lameness is given in Table 1. Radiographs were taken on the postoperative 10th, 30th, 45th days and the follow-up period was ended on 45th day. However, postoperative follow-up period of case no 5 has continued until day 58 due to infection.

Table 1. Scale for the assessment of lameness.

Score	Assessment
0	No lameness
1	Mild lameness
2	Moderate lameness
3	Severe lameness
4	No weight bearing

Results

Cases have involved 6 dogs of various ages between 2 and 8. The average age of the cases was calculated to be 3.66. In the study, 4 of the 6 cases were identified as male and 2 as female, 5 as crossbreed and 1 as an *Anatolian Sheep Dog* (Kangal). 6 × 150 mm interlocking nail was used in 1 case (case no.2), 6 × 160 mm in 2 cases (cases no.1 and 6) and 6 × 170 mm in 3 cases (cases no. 3, 4 and 5). Case descriptions, the diameters, and the lengths of interlocking nails used are given in Table 2.

Postoperative radiographs were taken on 10th, 30th, 45th days, and patients were clinically controlled. On the postoperative 10th day, no weight bearing was observed in case no 1. It was also observed that cases no 3, 4 and 5 had severe lameness, cases no 2 and 6 had mild lameness. On the postoperative 30th day, it was reported that case no 5 had moderate, case no 1 had mild lameness where as cases no 2, 4 and 6 had no lameness.

Table 2. Age, gender, breed, cause of lesion, diameters and lengths of the pins.

Case no	Age/Year	Gender	Breed	Cause of lesion	Diameters of pins	Lengths of pins
1	2	M	Crossbreed	Unknown	6 mm	160 mm
2	2	M	Crossbreed	Unknown	6 mm	150 mm
3	4	F	<i>Kangal</i>	Traffic accident	6 mm	170 mm
4	2	M	Crossbreed	Traffic accident	6 mm	170 mm
5	8	F	Crossbreed	Unknown	6 mm	170 mm
6	3	M	Crossbreed	Traffic accident	6 mm	160 mm

On the postoperative 45th day, no lameness was observed in cases no 1, 2, 4 and 6. However, mild lameness was observed in case no 5 with purulent discharge where the pins of the external fixator have been penetrated to the skin. In radiological examination infection was observed in tibia. After removing the acrylic fixator and the interlocking pin, antibiotic treatment and splint bandahe were practiced for case no 5. On the postoperative 58th day, no evidence of infection was observed in case no 5 and the treatment was finalized. Lameness results of the cases on the postoperative 10th, 30th and 45th days are given in Table 3. (Fig 2,3).

Table 3. Lameness assessment scale for the cases on the postoperative 10 th, 30 th and 45 th days.

Case no	10th day	30th day	45th day
1	4	1	0
2	1	0	0
3	3	-	-
4	3	0	0
5	3	2	2
6	1	0	0

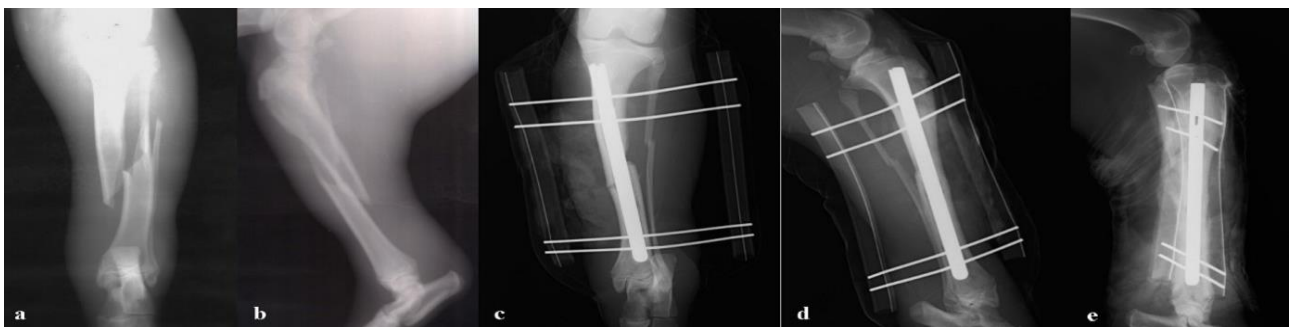


Figure 2. Preoperative and postoperative radiographs of case no 4. **a** and **b**. preoperative, **c**. and **d**. postoperative 10th day, **e**. postoperative 45th day radiographs of case 4.

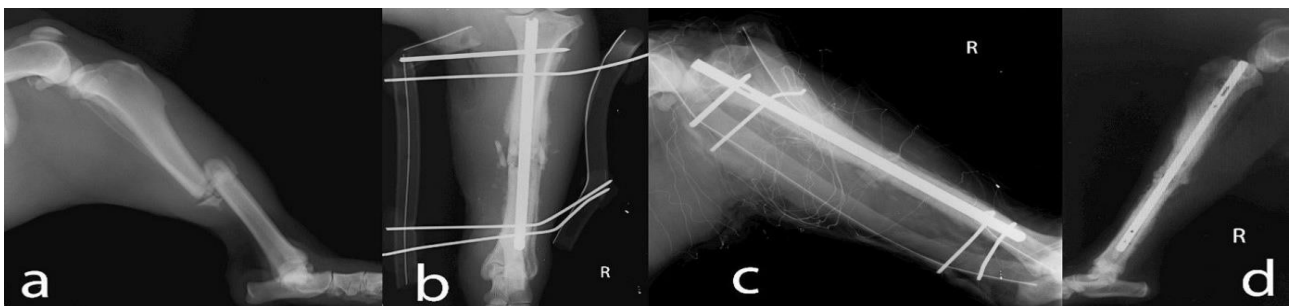


Figure 3. Preoperative and postoperative radiographs of case no 5. **a**. Preoperative, **b** and **c**. postoperative 30th day, **d**. postoperative 45th day radiographs after pins and external fixator removing of case 5.

Discussion

Early weight bearing in the recovery period utilizes the treatment process. It also contributes to increase stability in the fracture line and this can be achieved by using a combination of an external fixator and interlocking nail. According to the researches carried out, early weight bearing in the recovery period can be achieved by using fixation systems that enable to reduce micro motions in the fracture line (Lu et al., 2009). Micro motions cause instability which is quite difficult to be prevented by fixation techniques such as interlocking nailing. According to a study, using only type I external

fixator, without combining with an interlocking nail, could not prevent instability caused by micro motions in the fracture line (Piórek et al., 2012).

In the study, interlocking nails of 6 mm diameter and of various lengths, Steinmann pins of 2-2.5 mm that were passed through the screw holes on interlocking nails have been used by combining with acrylic to form a external fixator. Via this application, it is expected that micro motions mentioned in literature will be avoided and early weight bearing in the healing process will be observed. Postoperative clinical and radiological examinations of the study

were performed on days 10th, 30th and 45th. In order to carry out the lameness assessment scores between 0 and 4 were given to the cases. In accordance with this, on the postoperative 10th day follow up it was observed that there was no weight bearing in case no 1, while weight bearing was observed in all other cases. On the postoperative 30th day, it was reported that cases no 2, 4 and 6 have weight bearing. In case no 1 mild and in case no 5 moderate lameness was observed. Case no 3 couldn't be followed up on the postoperative 30th day. On the postoperative 45th day, no lameness was recorded in cases no 1, 2, 4 and 6. Moderate lameness due to infection was observed in case no 5. Considering this data, healing was achieved in a short time in cases where weight bearing has been observed. The results of the study are consistent with literature.

Internal fixation of bone fractures by metallic plates and screws is a common and a reliable treatment method. However, these metallic implants need to be removed just after the healing process is completed. Unless implants, such as plate and screws, are removed, some spontaneous bone fractures may occur in the bone tissue just below the implants, even with normal weight bearing. On the other hand, screw loosening and inflammatory reactions due to corrosion can be seen (Bos et al., 1991).

Screw holes which are placed on interlocking pins, also reduce the resistance of the pin. If the screw holes are close to the fracture line, the possibility of bone fractures and implant failures can emerge (Bos et al., 1991). The hole on the proximal part of the distal fragment is where the pin break is mostly observed. During the postoperative period, complications such as pin breaks, misplacement of the screws or loose screw implementations can be observed (McLaughlin, 1999).

The weight bearing ratio between the bone and the interlocking pin increases on the bone as the bone heals. The reason for this is that the callus formation in the fracture zone increases the moment of stability and thus transfers weight from the implant to the bone (Dueland et al., 1996).

In standard interlocking nailing technique, cortical screws are used for fixing the pin to the bone. The pin and screws are not generally removed from related bone after healing. In the study, due to the Steinmann pins was applied to the holes on the pin instead of the screw, there was no necessity to open the hole zone after operation to remove the pins. In addition, as the callus formation increases, the stress on the implant decreases. Therefore, external fixators applied from the holes on the pins were

combined with the interlocking pins instead of the screws used in the standard treatment method. Thus, the stress on the pins was shared with the external fixator. On the other hand, the external fixators were removed after fracture healing and long-term spontaneous bone fractures caused by the screws which used in standard interlocking nailing technique were prevented. There were no complications due to the implant in the postoperative period. In this study, two objectives have been aimed by using interlocking pin and acrylic external fixator combinations for the treatment of diaphyseal tibial fractures: The first objective is to reduce complications due to implant loads. The second objective is to reduce the risk of healing losses due to torsional and bending forces as a result of early weight bearing during the postoperative period.

Conclusions

Although interlocking nailing is used safely in the treatment of restless and aggressive dogs that need a rigid fixation and where the postoperative care is difficult and crucial, interlocking nailing and external fixator applications can be combined in order to prevent instability due to torsional and bending forces and to reduce the amount of foreign bodies on the bone. This combination can also be used for preventing inflammatory reactions due to the usage of metal screws.

During the postoperative period of external fixator applications, antibiotherapy and caring under hygienic conditions are quite important for reducing the risk of infection.

As a result, interlocking nailing, which is an alternative to intramedullary pin applications, has been successfully used when combined with external fixators. Combination of interlocking nailing and external fixators can be considered as an alternative treatment method as it prevents instability and provides a rapid healing process.

References

- Bergsma** EJ, Rozema FR, Bos RRM, De Bruijn WC (1993) Foreign Body Reactions to Resorbable Poly(L-Lactide) Bone Plates and Screws Used for the Fixation of Unstable Zygomatic Fractures. *J Oral Maxillofac Surg* 51:666-670. [https://doi.org/10.1016/S0278-2391\(10\)80267-8](https://doi.org/10.1016/S0278-2391(10)80267-8)
- Bhat** AK, Rao SK, Bhaskaranand K (2006) Mechanical failure in intramedullary interlocking nails. *J Orthop Surg*

14(2):138-41. <https://doi.org/10.1177/230949900601400206>

Bos RRM, Rozema FR, Boering G, Nijenhuis AJ, Pennings AJ, Verwey AB, Nieuwenhuis P, Jansent HWB (1991) Degradation of and tissue reaction to biodegradable poly (Llactide) for use as internal fixation of fractures: a study in rats. *Biomaterials* 12(1):32-36. [https://doi.org/10.1016/0142-9612\(91\)90128-W](https://doi.org/10.1016/0142-9612(91)90128-W)

Dueland RT, Berglund L, Vanderby R, Chao EYS (1996) Structural Properties Of Interlocking Nails, Canine Femora, And Femur Interlocking Nail Constructs. *Vet Surg* 25:386-396. <https://doi.org/10.1111/j.1532-950X.1996.tb01432.x>

Duhautois B (2003) Use of Veterinary Interlocking Nails for Diaphyseal Fractures in Dogs and Cats: 121 cases. *Vet Surg* 32(1), 8-20. <https://doi.org/10.1053/jvet.2003.50008>

Fossum TW (2013) Fundamentals of Orthopedic Surgery and Fracture Management. In: *Small Animal Surgery, 4th Edn.* Mosby Inc., St. Louis, pp 1082-1083.

Goett SD, Sinnott MT, Ting D, Basinger RR, Haut RC, Dejardin LM (2007) Mechanical comparison of an interlocking nail locked with conventional bolts to extended bolts connected with a type Ia external skeletal fixator in a tibial fracture model. *Vet Surg* 36:279-286. <https://doi.org/10.1111/j.1532-950x.2007.00265.x>

Lu Y, Nemke B, Lorang DM, Trip R, Kobayashi H, Markel MD (2009) Comparison of a new braid fixation system to an interlocking intramedullary nail for tibial osteotomy repair in an ovine model. *Vet Surg* 38: 467-476. <https://doi.org/10.1111/j.1532-950X.2009.00517.x>

McLaughlin R (1999) Internal Fixation: Intramedullary Pins, Cerclage Wires, and Interlocking Nails. *Vet Clin North Am Small Anim Pract* 29(5):1097-1116. [https://doi.org/10.1016/S0195-5616\(99\)50104-6](https://doi.org/10.1016/S0195-5616(99)50104-6)

Piórek A, Adamiak Z, Jaskólska M, Zhalniarovich Y (2012) Treatment of comminuted tibial shaft fractures in four dogs with the use of interlocking nail connected with type I external fixator. *Pol J Vet Sci* 15:661-666. <https://doi.org/10.2478/v10181-012-0103-6>

Stiffler KS (2004) Internal Fracture Fixation. *Clin Tech Small Anim Pract* 19:105-113. <https://doi.org/10.1053/j.ctsap.2004.09.002>

Van der Elst M, Klein CPAT, De Blicke-Hogervorst JM, Patka P, Haarman HJ.Th.M (1999) Bone tissue response to biodegradable polymers used for intra medullary fracture fixation: A long-term in vivo study in sheep femora. *Biomaterials* 20:121-128. [https://doi.org/10.1016/S0142-9612\(98\)00117-3](https://doi.org/10.1016/S0142-9612(98)00117-3)